

Hashimoto's Thyroiditis-Association with Eosinophilic Infiltration in FNAC

Manish K. Bansal, Varun Gupta*, Rajni Bharti and Shrishti Soni

Department of Medicine, S. N. Medical College Agra, India

**Corresponding author*

Abstract

To assess whether an eosinophilic infiltration of the thyroid gland has a higher association with diffuse thyroid swellings especially Hashimoto's thyroiditis and search for more cytological clues to increase the sensitivity of diagnosis of diffuse swellings of thyroid gland on Fine needle aspiration cytology (FNAC). A total of 80 cases were studied. Aspirates from these cases were studied for cytomorphological features, all the cases were divided into two groups- cases and control. The cases diagnosed as Hashimoto's thyroiditis were included in the case group and cases diagnosed as other benign swellings except Hashimoto's thyroiditis were included in the control group. 40% of the cases showed an average of more than 1 eosinophil per HPF but none of the cases in the control group showed an average more than 1. Thus, we saw that number of eosinophils per HPF in the smears diagnosed as Hashimoto's thyroiditis was found higher than in the smears from the control group. We also observed that the average ratio of eosinophils to neutrophils in the smears diagnosed as Hashimoto's thyroiditis was found to be significantly greater than in smears from the control group. Among the patients with Hashimoto's thyroiditis 80-90% have high titers of antithyroglobulin antibodies. Besides serological diagnosis presence of eosinophil per HPF increases the sensitivity of cytological diagnosis of Hashimoto thyroiditis.

Article Info

Accepted: 04 September 2017
Available Online: 20 October 2017

Keywords

Hashimoto,
Eosinophil,
Antithyroglobulin.

Introduction

Hashimoto's thyroiditis is the commonest of painless hypothyroidism in areas of iodine sufficiency. Hashimoto's thyroiditis is the second most common thyroid lesion diagnosed by cytology after endemic goiter. FNAC is highly cost effective (1) in diagnosing Hashimoto's thyroiditis with a diagnostic accuracy rate of 92% (2). Hashimoto's thyroiditis is likely to be missed in smears showing cytological evidence of hyperplasia or abundant colloid. Lymphocytic infiltration of the gland in Grave's disease may result in an overlap (3) of cytological appearances with Hashimoto's thyroiditis.

We observed thyroid tissue eosinophilia in many of the cytology smears that were diagnosed as Hashimoto's thyroiditis. This prompted us to undertake this study to assess if there was a significant association between eosinophilic infiltration of thyroid gland and diffuse lesions of thyroid especially Hashimoto's thyroiditis.

Materials and Methods

This study was carried out in department of Medicine, S N Medical College, Agra. Cases included diffuse thyroid lesions mainly Hashimoto's thyroiditis, Colloid goitre, florid lymphocytic thyroiditis, chronic lymphocytic

thyroiditis and sub-acute thyroiditis. Neoplastic lesion was excluded. A total of 80 cases were studied. Aspirates from these cases were studied for cytomorphological features, areas of cytological overlap and compared for presence of eosinophils. For this purpose, all the cases were divided into two groups- cases and control.

The cases diagnosed as Hashimoto's thyroiditis were included in the case group and cases diagnosed another benign swelling except Hashimoto's thyroiditis mainly comprising colloid goiter, chronic lymphocytic thyroiditis, florid lymphocytic thyroiditis and sub-acute thyroiditis were included in the control group. 40% of the cases showed an average of more than 1 but none of the cases in the control group showed an average more than 1 eosinophil per HPF. Thus, we saw that number of eosinophils per HPF in the smears diagnosed as Hashimoto's thyroiditis was found higher than in the smears from the control group. We also observed that the average ratio of eosinophils to neutrophils in the smears diagnosed as Hashimoto's thyroiditis was found to be significantly greater than in smears from the control group.

Observations

Frequency of different lesions diagnosed

40 out of 80 cases (50%) were diagnosed as Hashimoto's thyroiditis. 19/80 (23.75%) of cases were of Colloid goiter, the second most frequent diagnosis. Florid and Chronic Lymphocytic thyroiditis accounted for 9/80 (11.25%) and 8/80 (10%) of cases respectively. Both of these entities were almost equally frequent. Only 4/80 (05%) of the cases were diagnosed as sub-acute thyroiditis.

The above graph depicts a comparison of average number of eosinophils per HPF between the case group and control group. 42.5% cases in the control group showed an average of 0 whereas in case group only 12.5% cases showed an average of 0.22.5% of cases showed an average between 0.6-1.0 but in the control group, only 10% cases were found to have an average between 0.6 to 1.0. 40% of the cases showed an average of more than 1 but none of the cases in the control group showed an average more than 1.

Thus, we saw that number of eosinophils per HPF in the smears diagnosed as Hashimoto's thyroiditis was found higher than in the smears from the control group.

The table 1 and graph depicts a comparison of average ratio of eosinophils to neutrophils per HPF between the case group and the control group. 60% of the cases in the control group showed an average ratio of eosinophils to neutrophils per HPF from 0-0.1 whereas in case group only 27.5% cases showed an average from 0-0.1. 12.5% of cases showed an average between 0.11-0.2 but in the control group 27.5% cases were found to have an average between 0.11-0.2. 30% of the cases showed an average of more than 0.5 but none of the cases in the control group showed an average more than 0.5.

Thus, we observed that the average ratio of eosinophils to neutrophils in the smears diagnosed as Hashimoto's thyroiditis was found to be significantly greater than in smears from the control group.

The above findings were then analyzed using unpaired t-test (SPSS software for Windows - version 15.0). On applying the test the two-tailed P value was less than 0.0001 and by conventional criteria; this difference is considered to be extremely statistically significant.

Confidence interval: The mean of Group One minus Group Two equals 0.508. 95% confidence interval of this difference was from 0.316 to 0.699 Intermediate values used in calculations: $t = 5.2753$; $df = 78$; standard error of difference = 0.096.

Thus, eosinophilic infiltration of the thyroid had higher association with Hashimoto's thyroiditis than the thyroid lesions in the control group.

It was observed that there was an overlap in the cytomorphological features of various thyroid lesions. 5/40 (12.5%) cases of Hashimoto's thyroiditis were confused with sub-acute thyroiditis due to presence of giant cells and epithelioid cells in the former.

The diagnosis was difficult in 2/40 (05%) cases of Hashimoto's thyroiditis with abundant colloid in the background which overlapped with colloid goiter causing confusion in diagnosis.

Presence of fire flares in 8/40 (20%) cases of Hashimoto's thyroiditis caused confusion with the diagnosis of Primary Hyperplasia or Grave's disease.

Presence of mixed lymphoid infiltrate in the background of Hashimoto's thyroiditis, florid lymphocytic thyroiditis as well as chronic lymphocytic thyroiditis made it difficult to render a definite diagnosis.

In presence of these cytologic overlaps one clue to the diagnosis was in the form of eosinophils in the smear, whose presence favored the diagnosis of Hashimoto's thyroiditis.

Results and Discussion

Hashimoto thyroiditis is an autoimmune disease present with a nontender goiter, hypothyroidism, and an elevated thyroid peroxidase antibody level.

Majority of patients have clinical features of hypothyroidism with painless goiter. The onset is usually insidious, and the patient may become aware of symptoms only when euthyroidism is restored

In Hashimoto thyroiditis TSH levels are increased, FT4 level decreased and FT3 levels are decreased in later stage. FT3 levels may be normal in 25% of cases. The titre of TPO antibody correlates with degree of lymphocytic infiltration in Hashimoto thyroiditis (Singh *et al.*, 2009). TSH estimation and antibody titre provides the diagnosis in 90-95% of patients.

If there is any doubt about the cause of a goiter associated with hypothyroidism, FNA biopsy can be used to confirm the presence of autoimmune thyroiditis.

FNAC is the first line diagnostic test for evaluation of goiter. FNAC is the most accurate, rapid and probably safer than other lab test providing diagnostic information via cytology, Gram stain, and bacterial and acid-fast bacilli cultures. The sensitivity and specificity of fine-needle aspiration biopsy in detecting a malignancy range from 77% to 97% and 93% to 100%, respectively. It provides reliable distinction between colloid goiter and Hashimoto's thyroiditis. Singh *et al.*, (2009) found that Grading of thyroiditis and lymphocytic infiltration showed no correlation with clinical severity of Hashimoto's thyroiditis, while a high lymphoid: epithelial ratio was strongly correlated with thyroid peroxidase positivity and thyroid peroxidase positivity showed strong association with Hashimoto's thyroiditis. Maheshwari Ekambaram *et al.*, (2010) observed thyroid tissue eosinophilia in many of the FNAC smears of Hashimoto's thyroiditis.

The prevalence of Hashimoto on the basis of clinical diagnosis is about 0.8% (Tunbridge *et al.*, 1977) but based on cytology the prevalence of Hashimoto thyroiditis seems to be 13.4% (AncaStai *et al.*, 2010) so it can be hypothesized that cytological diagnosis of Hashimoto's may precede clinical diagnosis that is diagnosing the disease cytologically when the patient is clinically asymptomatic.

Fig.1 Frequency of diagnosis rendered

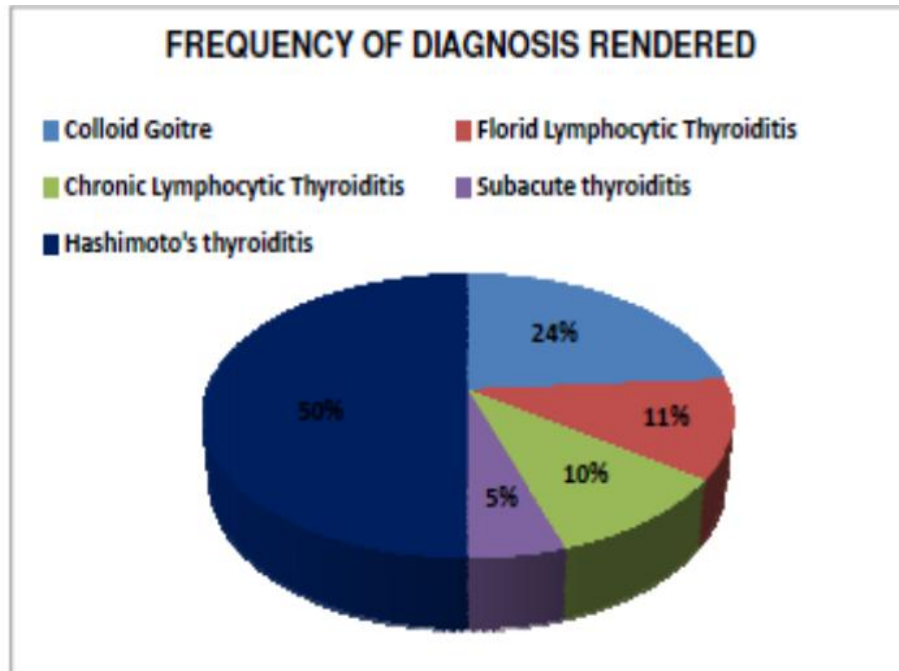


Fig.2 Average no of eosinophils in both cases and control group

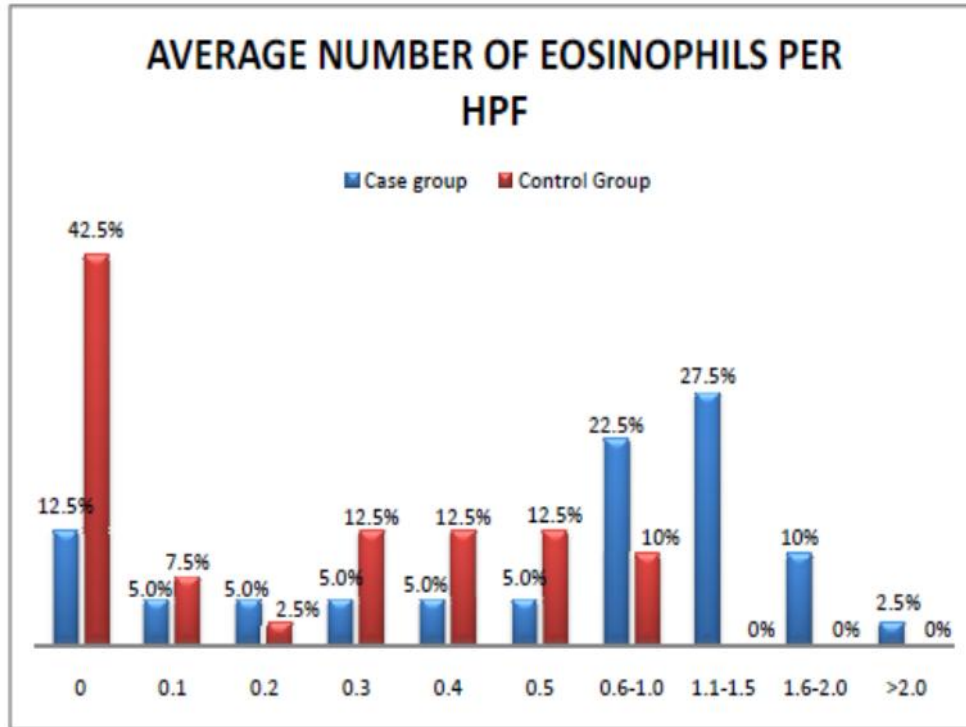


Table.1
COMPARISON OF AVERAGE RATIO OF EOSINOPHILS TO NEUTROPHILS PER HPF IN THE CASE GROUP AND THE CONTROL GROUP

AVERAGE RATIO OF EOSINOPHILS TO NEUTROPHILS PER HPF	CASE GROUP (CASES DIAGNOSED AS HASHIMOTO'S THYROIDITIS)	CONTROL GROUP (CASES DIAGNOSED OTHER THAN HASHIMOTOS THYROIDITIS)
0-0.1	11(27.5%)	24(60%)
0.11-0.20	05(12.5%)	11(27.5)
0.21-0.30	04(10%)	03(7.5%)
0.31-0.40	05(12.5%)	01(2.5%)
0.41-0.50	03(7.5%)	01(2.5%)
0.51-0.60	01(2.5%)	00(0%)
0.61-0.70	03(7.5%)	00(0%)
0.71-0.80	02(5.0%)	00(0%)
0.81-0.90	01(2.5%)	00(0%)
0.91-1.0	02(05%)	00(0%)
1.1-2.0	03(7.5%)	00(0%)

Fig.3 Average ratio of Eosinophils to Neutrophils per HPF

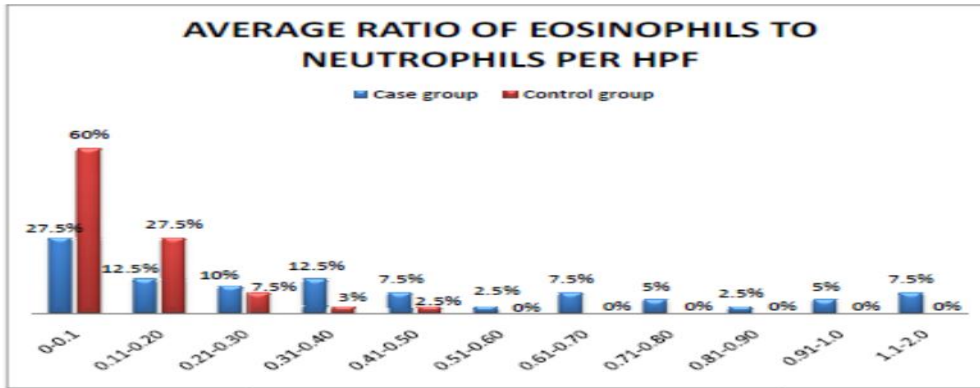


Fig.4 A comparison of average Eosinophils per HPF with other study (case group)

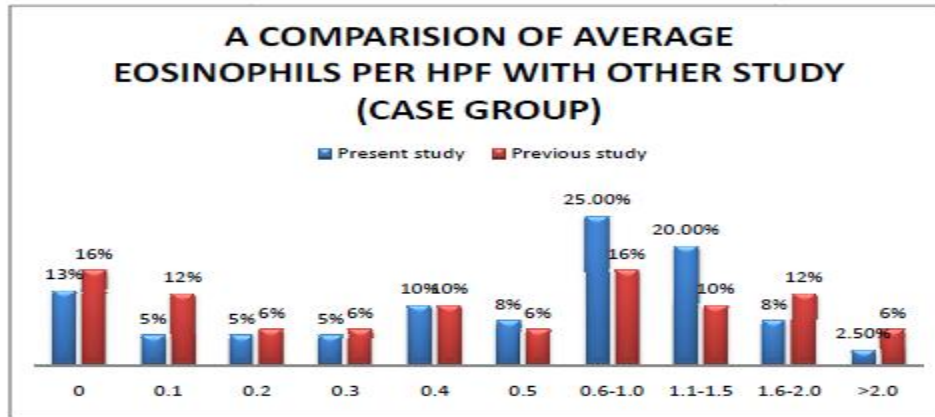


Fig.5 A comparison of average Eosinophils per HPF with other study (control group)

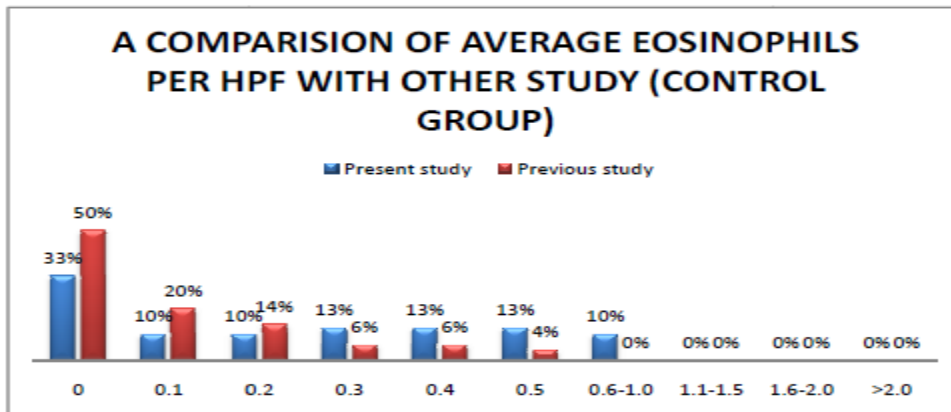


Fig.6 A comparison of average ratio of Eosinophils to neutrophils per HPF with other study (case group)

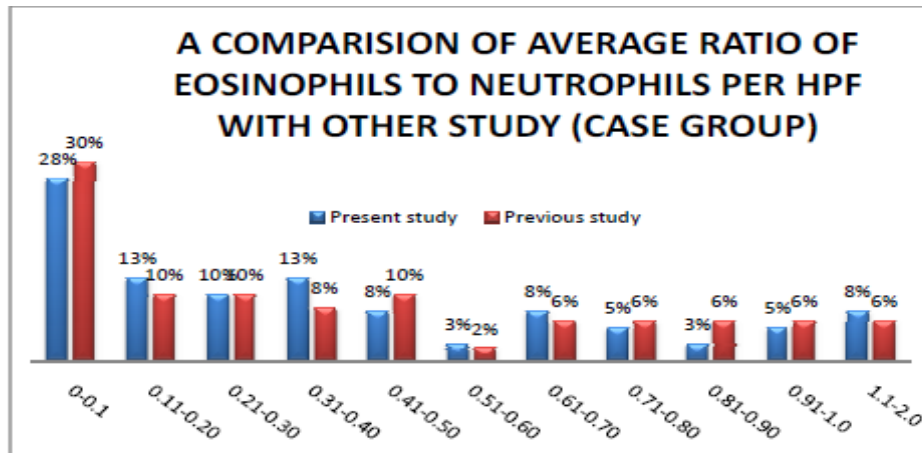
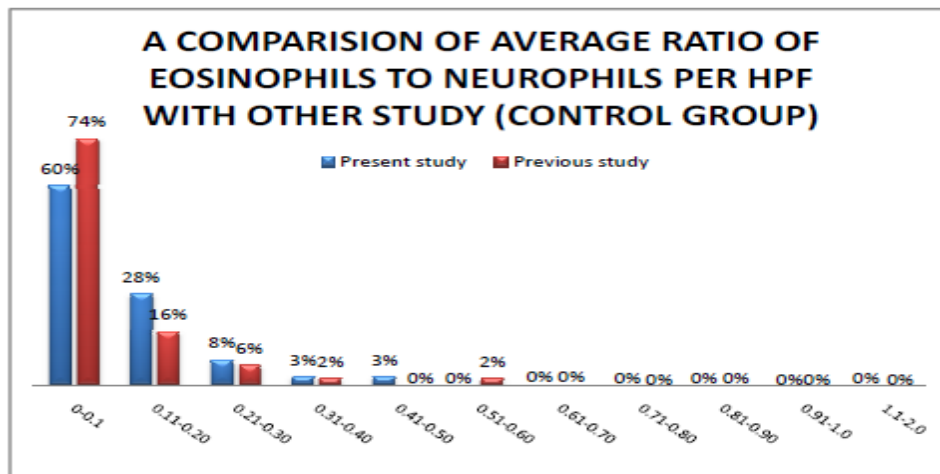


Fig.7 A comparison of average ratio of eosinophils to neutrophils to neutrophils per HPF with other study (control group)



Benefit of cytological methods is diagnosing asymptomatic or subclinical hypothyroidism which is otherwise missed. An anti-TPO and/or antithyroglobulin antibody titres were present in only 50% of patients with euthyroid, cytology- proven Hashimoto thyroiditis so it is understood that early Hashimoto's autoimmune process might be clinically missed was reported (8). Weight loss is also a scenario where TSH measurement may be misleading. The elevated TSH that would be expected in Hashimoto's thyroiditis was blunted by weight loss associated with Anxiety Neurosis was reported early (9). Consequences of untreated subclinical hypothyroidism are dyslipidemia, coronary artery disease, CHF, cognitive dysfunction and

neuropsychiatric symptoms and progression to overt symptomatic hypothyroidism. There is possible association between high TSH and fetal wastage as (10) well as neuro-psychological complications in the offspring due to thyroid insufficiency.

These issues, together with the awareness that sub-clinical and clinical hypothyroidism associates with cardiovascular and neuropsychiatri comorbidities, make finding high prevalence of Hashimoto thyroiditis on cytology, especially in euthyroid patients clinically significant.

Pathogenesis of Hashimoto thyroiditis is present in an unexpectedly large number of individuals. Many of these individuals carry a non-clinically manifested process. Biopsy proven Hashimoto thyroiditis in asymptomatic, clinically disease-free patients is a condition still undefined. Recognition of this entity emerges as necessary at least in patients at risk for hypothyroid complications (i.e. pregnancy). If the cytology of Hashimoto thyroiditis represents a chronic active inflammatory state which is increase percentage of eosinophils in our study, TSH elevations within normal limits may represent a manifestation of a common underlying process.

So we conducted a study to consolidate results of previous studies on cytological examination of thyroid and to find out more conclusive features (eosinophilia) that will help in diagnosing Hashimoto's thyroiditis.

We found that there was an overlap in the cytomorphological features of various thyroid lesions. 5/40 (12.5%) cases of Hashimoto's thyroiditis were confused with sub-acute thyroiditis due to presence of giant cells and epithelioid cells in the former. The diagnosis was difficult in 2/40 (05%) cases of Hashimoto's thyroiditis with abundant colloid in the background which overlapped with colloid goitre causing confusion in diagnosis. Presence of fire flares in 8/40 (20%) cases of Hashimoto's thyroiditis caused confusion with the diagnosis of Primary Hyperplasia or Grave's disease. Presence of mixed lymphoid infiltrate in the background of Hashimoto's thyroiditis, florid lymphocytic thyroiditis as well as chronic lymphocytic thyroiditis made it difficult to render a definite diagnosis. In presence of these cytologic overlaps one clue to the diagnosis was in the form of eosinophils in the smear, whose presence favored the diagnosis of Hashimoto's thyroiditis.

Our study has shown a significant infiltration of the thyroid gland with eosinophils in case of Hashimoto's thyroiditis than in cases with colloid goiter, florid lymphocytic thyroiditis, chronic lymphocytic thyroiditis and Sub-acute thyroiditis. This eosinophilic infiltration was observed in lymphoid aggregate, thus ruling out admixture with blood. This is a finding that has rarely been reported. We sincerely hope that further larger and

independent studies will help us in understanding the significance of eosinophilic infiltration of the thyroid gland in cases of Hashimoto's thyroiditis.

References

1. Frable WJ: Thin-needle aspiration biopsy. Saunders, Philadelphia, 1983.
2. Ackerman M *et al.*, Sensitivity and specificity of fine needle aspiration cytology in the diagnosis of tumours of the thyroid gland. *ActaCytol* 29: 850-855, 1985.
3. Bhalotra R, Jayaram G. Overlapping morphology in thyroiditis (Hashimoto's and subacute) and Grave's disease. *Cytopathology* 1990; 1: 371-2.
4. Singh N, Kumar S, Negi VS, Siddharaju N. Cytomorphological study of Hashimoto's thyroiditis and its serological correlation. *ActaCytol.* 2009; 53: 507-16.
5. Ekambaram M, Bipin Kumar, Nitlotpal Chowdhary, N Siddharaju, Surendra Kumar. Significance of eosinophils in diagnosing Hashimoto's thyroiditis on FNAC. *Indian Journal of Pathology and Microbiology* 2010; 53: 482-85.
6. Tunbridge WM, Evered DC, Hall R, Appleton D, Brewis M, Clark F, Evans JG, Young E, Bird T, Smith PA: The spectrum of thyroid disease in a community: the Wickham survey. *ClinEndocrinol (Oxf)* 1977, 7:481-493.
7. AncaStaii, Sarah Mirocha, Kristina Todorova-Koteva, Simone Glinberg, Juan C Jaume. 2010. *Endocrinology, Diabetes and Metabolism*, Department of Medicine, School of Medicine and Veterans Affairs Medical Center, University of Wisconsin Madison, Madison WI 53792, USA.
8. Poropatich C, Marcus D, Oertel YC: Hashimoto's thyroiditis: fine-needle aspirations of 50 asymptomatic cases. *Diagn Cytopathol* 1994, 11:141-145.
9. Smalls-Mantey A1, Steinglass J, Primack M, Clark-Hamilton J, Bongiovi M. Hypothyroidism due to Hashimoto's thyroiditis masked by anorexia nervosa. *J Eat Disord.* 2015 May 6. doi: 10.1002/eat.22420
10. Benhadi N, Wiersinga WM, Reitsma JB, Vrijkotte TG, Bonse GJ: Higher maternal TSH levels in pregnancy are associated with increased risk for miscarriage, fetal or neonatal death. *Eur J Endocrinol* 2009, 160: 985-991.

How to cite this article:

Manish K. Bansal, Varun Gupta, Rajni Bharti and Shrishti Soni. 2017. Hashimoto's Thyroiditis-Association with Eosinophilic Infiltration in FNAC. *Int.J.Curr.Res.Aca.Rev.* 5(10), 62-68.

doi: <https://doi.org/10.20546/ijcrar.2017.510.010>